

## Lung Ablation in a Patient with Prior Pneumonectomy: A Case Report

**Moein Moradpour, MD<sup>1</sup> and Stephen J. Hunt, MD PhD, FSIR<sup>1,2\*</sup>**

<sup>1</sup>Department of Radiology, Hospital of the University of Pennsylvania, University of Pennsylvania, USA

<sup>2</sup>Penn Image-Guided Interventions Laboratory, Perelman School of Medicine, University of Pennsylvania, Department of Radiology, Hospital of the University of Pennsylvania, USA

\***Corresponding author:** Stephen J. Hunt, MD, PhD, FSIR, Assistant Professor of Radiology, Hospital of the University of Pennsylvania, Philadelphia, Pennsylvania 19104, USA, Tel: +1(650)7998222

### Abstract

Surgical resection remains the primary approach for recurrent lung cancer, yet cryoablation has emerged as a valuable option for inoperable cases. This case report demonstrates the successful utilization of percutaneous cryoablation in treating a solitary pulmonary nodule (SPN) in a 47-year-old female with prior pneumonectomy for non-small cell lung cancer (NSCLC). Given the patient's limited lung reserve, resection was deemed high risk by the surgical oncologist. Thus, the patient was referred to interventional oncology for lung ablation. The procedure was successful without complication. At 24-month follow-up, there was no evidence of recurrence. Prior studies underscore favorable outcomes in post-pneumonectomy patients undergoing lung ablation with low complication

rates. Overall survival rates suggest percutaneous ablation is a viable alternative in this population.

**Keywords:** Solitary pulmonary nodule; Pneumonectomy; Percutaneous ablation; Case report

### Introduction

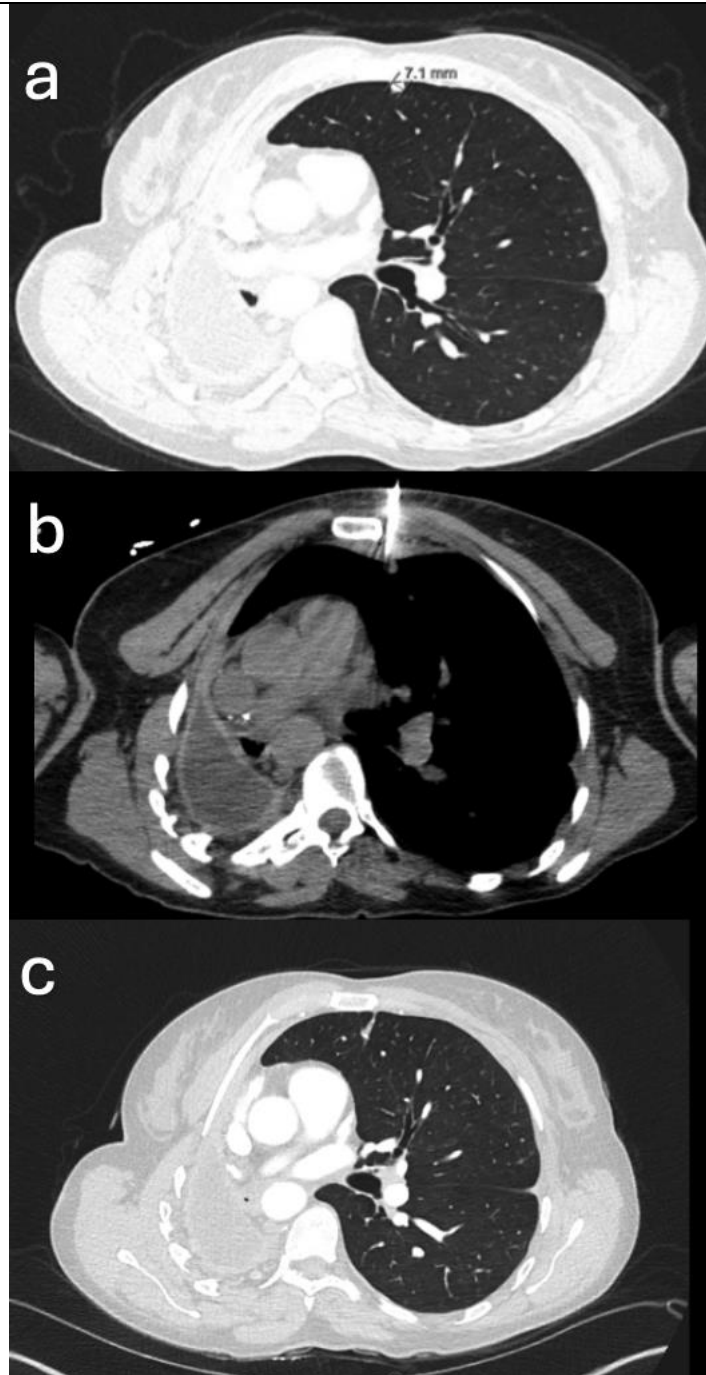
Surgical resection remains the recommended treatment for recurrent lung cancer. Cryoablation is an option for treating lesions in patients who are poor surgical candidates. Cryoablation preserves surrounding healthy lung tissue while effectively destroying the targeted nodule. Studies have indicated a minimal impact on pulmonary function, which is crucial for patients with limited lung reserve, including post-pneumonectomy patients. Cryoablation consists of alternating cycles of freezing and thawing, leading to direct cellular and vascular injury resulting in tumor death. This case report

describes the application of cryoablation in treating a solitary pulmonary nodule in a patient who had previously undergone pneumonectomy due to lung adenocarcinoma.

### **Case Presentation**

Per institutional guidelines, IRB exemption was waived for this clinical case report. The patient provided consent for reporting of her case. A 46-year-old female with a history of Non-Small Cell Lung Cancer (NSCLC) status post right pneumonectomy 5 years prior, presented with a growing 7 mm left anterior upper lobe nodule suspicious for neoplasm. Due to her previous pneumonectomy and limited pulmonary reserve, she was considered not to be a candidate for surgical excision. She was referred to the interventional clinic for consideration of percutaneous cryoablation. The patient was treated under conscious sedation using a combination of intravenous midazolam and fentanyl.

Using CT guidance, anesthesia of the skin and soft tissue was performed with 10 ml of buffered 1% lidocaine, and pleural anesthesia was performed with 20 ml of 0.5% bupivacaine. Under CT-guidance, a single Galil IceSphere cryoprobe was inserted into the nodule. A triple freeze-thaw cycle consisting of active freeze of 5 minutes followed by a passive thaw of 5 minutes with interval CT scans was performed. The probe was removed following the final thawing of the ice ball and a final scan was performed to document the treatment zone and assess for complication. Chest radiograph performed two hours after intervention demonstrated no pneumothorax, and the patient was discharged to home. Follow-up 6-week PET-CT scan demonstrated post treatment changes without FDG uptake in the treatment zone. Serial CT scans over the following 24 months after cryoablation reported curvilinear scar without evidence of recurrence ([Figure 1](#)).



**Figure 1:** A) A 46-year-old female with prior right pneumonectomy secondary to non-small cell lung cancer presented with a growing 7 mm LUL nodule suspicious for neoplasm. B) A single Galil IceSphere cryoablation probe was used to ablate the tumor. C) 24 months after ablation demonstrated a curvilinear scar.

### Discussion

Cryoablation is an established treatment alternative for patient who are of untenable surgical risk. The

most common complications of cryoablation are pneumothorax and parenchymal hemorrhage. Complications are self-limited, easily managed, and

rarely require surgical intervention. Most importantly, lung function is preserved in the setting of cryoablation. Cryoablation is increasingly being used to manage patients with oligometastatic disease. In the SOLSTICE trial, 128 patients with 224 lung metastases were treated with percutaneous cryoablation [1]. Local recurrence-free response of the treated tumor was 85% at 12 months and 77% at 24 months. In the setting of recurrence, the secondary recurrence-free response was 91% at 12 months and 84% at 24 months [1]. In the ECLIPSE trial, 40 patients with lung metastases underwent cryoablation, showing strong local tumor control rates at 6 and 12 months (96.6% and 94.2%). The one-year overall survival rate was 97.5% [2]. Two case series have reported outcomes for patients after microwave and radiofrequency ablation of lung malignancies in post-pneumonectomy patients. Sofocleus and colleagues reported a series of 12 patients with a history of pneumonectomy undergoing RFA or microwave lung ablations in 16 sessions. Three patients died within 12 days of the procedure. Causes of death included hemothorax and pulmonary failure. The median time to primary local tumor progression in the surviving patients was 18 months, and the median overall survival was 21 months [3]. Yang and colleagues reported outcomes for a series of 11 post-pneumonectomy patients receiving microwave ablation for recurrent malignancy. There were no deaths within 30 days, however, 4 patients experienced local recurrences at one year of follow-up. Median overall survival was reported as 20 months, with 1-, 3-, and 4-year overall survival of 89%, 63%, and 42% [4]. Additional case reports have also documented successful RFA and microwave ablation in post-pneumonectomy patients [5-7]. Yamauchi and colleagues reported two cases of

cryoablation for pulmonary nodules in the residual lung after pneumonectomy. Neither patient experienced complication nor there was no recurrence in 2 and 4-year follow-ups [8]. To our knowledge, this is the third case of cryoablation of lung malignancy in a post-pneumonectomy patient, demonstrating safety and long term efficacy.

## Conclusion

This case report demonstrates cryoablation as a viable treatment option for lung malignancy in patients with a history of pneumonectomy. Cryoablation represents a minimally invasive approach that preserves healthy lung tissue, is less prone to complication than traditional surgery, and can provide a cure in this fragile patient population.

## References

1. Callstrom MR, et al. Multicenter Study of Metastatic Lung Tumors Targeted by Interventional Cryoablation Evaluation (SOLSTICE). *J Thorac Oncol.* 2020;15(7):1200-1209.
2. de Baere T, et al. Evaluating Cryoablation of Metastatic Lung Tumors in Patients--Safety and Efficacy: The ECLIPSE Trial--Interim Analysis at 1 Year. *J Thorac Oncol.* 2015;10(10):1468-74.
3. Sofocleous CT, et al. Pulmonary thermal ablation in patients with prior pneumonectomy. *Am J Roentgenol.* 2011;196(5):W606-W612.
4. Yang X, et al. Microwave ablation for lung cancer patients with a single lung: Clinical evaluation of 11 cases. *Thorac Cancer.* 2018;9(5):548-54.

5. Ambrogi MC, et al. Pulmonary radiofrequency ablation in a single lung patient. *Thorax*. 2006;61(9):828-9.
6. Wei Z, et al. Computed tomography-guided percutaneous microwave ablation of early stage non-small cell lung cancer in a pneumonectomy patient. *Thorac Cancer*. 2016;7(1):151-3.
7. Modesto A, et al. Radiofrequency ablation for non-small-cell lung cancer in a single-lung patient: case report and review of the literature. *Lung Cancer*. 2013;80(3):341-3.
8. Yamauchi Y, et al. Percutaneous cryoablation for pulmonary nodules in the residual lung after pneumonectomy: report of two cases. *Chest*. 2011;140(6):1633-37.

### **Citation of this Article**

Moradpour M and Hunt SJ. Lung Ablation in a Patient with Prior Pneumonectomy: A Case Report. *Mega J Case Rep*. 2026;9(7):2001-2005.

### **Copyright**

©2026 Moradpour M. This is an Open Access Journal Article Published under [Attribution-Share Alike CC BY-SA](#): Creative Commons Attribution-Share Alike 4.0 International License. With this license, readers can share, distribute, and download, even commercially, as long as the original source is properly cited.