

Unique Exfoliative Esophagitis Induced by Dabigatran

Sugiyama T^{1*}, Takashima Y² and Fujimani H²

¹Research Center, Health Sciences University of Hokkaido, Japan

²Department of Gastroenterology, Toyama University Hospital

***Corresponding author:** Toshiro Sugiyama, Research Center, Health Sciences University of Hokkaido, Ishikari, Japan

Clinical Image

A 68-year-old male patient was admitted at Department of Cardiology for the treatment of atrial fibrillation in our hospital [1]. After cryoablation, he was immediately taking dabigatran for preventing hypercoagulation under supine position on the bed [2]. At the day after tomorrow, he was feeling severe anterior chest pain and was consulted to our department. As ECG and blood test had showed normal findings, an upper endoscopy was conducted [3]. A sloughing longitudinal exfoliative esophagitis was observed in middle esophagus (**Figure 1**). These findings were typically caused by Dabigatran-Induced Esophagitis (DIE) [4]. He was taking the drug under supine position on the bed after the intervention treatment. Dabigatran capsule might be retained and released in the esophagus. Therefore, dabigatran-induced longitudinal exfoliative esophagitis might be occurred [5]. After taking proton-pump inhibitor and taking dabigatran at standing position, the esophagitis was rapidly improved. When taking dabigatran, the position might be important for avoiding esophageal retention.

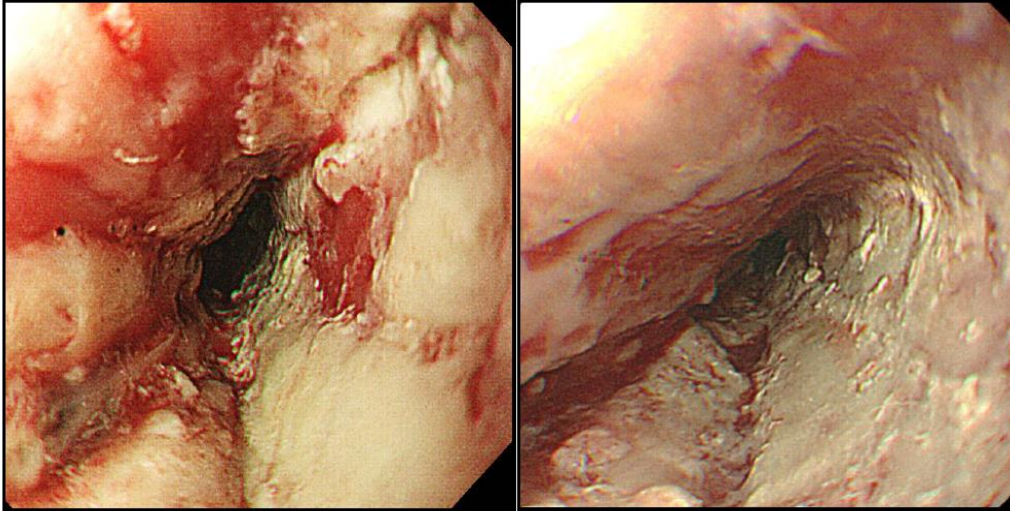


Figure 1: Exfoliative esophagitis in middle portion.

References

1. [Zhou Y, Dai Y, Lu L, Fu Z. Dabigatran-induced esophagitis: A case report. *Medicine \(Baltimore\)*. 2020;99\(17\):e19890.](#)
2. [Matsumoto Y, Senda E, Yamada H. Dabigatran-Induced Esophagitis Associated With Vomiting. *Am J Gastroenterol*. 2019;114\(4\):548.](#)
3. [Kajihara Y. Dabigatran-induced esophagitis. *Cleve Clin J Med*. 2019;86\(5\):303-304.](#)
4. [Yoshimitsu M, Sawada T, Kobayashi T, Yamagishi M. Dabigatran-induced Exfoliative Esophagitis. *Intern Med*. 2016;55\(13\):1815.](#)
5. [Toya Y, Nakamura S, Tomita K, Matsuda N, Abe K, Abiko Y, et al. Dabigatran-induced esophagitis: The prevalence and endoscopic characteristics. *J Gastroenterol Hepatol*. 2016;31\(3\):610-4.](#)

Citation of this Article

Sugiyama T, Takashima Y and Fujimani H. Unique Exfoliative Esophagitis Induced by Dabigatran. *Mega J Case Rep*. 2024;7(5):2001-2002.

Copyright

©2024 Sugiyama T. This is an Open Access Journal Article Published under [Attribution-Share Alike CC BY-SA](#): Creative Commons Attribution-Share Alike 4.0 International License. With this license, readers can share, distribute, and download, even commercially, as long as the original source is properly cited.