

Next-Generation Sequencing Technology for the Diagnosis of Cryptococcal Meningitis in a Heart Valve Surgery Female: A Case Report

Jingji Huang¹, Manli Liu², Songsong Zhang², Enyu Yang², Xueyan Wu², Maodi Gong², Xianqing Shi² and Jing Wu^{2*}

¹The Second Clinical Medical College, Guizhou University of Traditional Chinese Medicine, Guiyang 550000, Guizhou Province, China

²Intensive Care Unit, Guizhou Provincial People's Hospital, Guiyang 550000, Guizhou Province, China

***Corresponding author:** Jing Wu, PhD, Associate Professor, Intensive Care Unit, Guizhou Provincial People's Hospital, No. 83 Zhongshan East Road, Guiyang 550000, Guizhou Province, China, Tel: 13984376424; E-mail: saidiny1120@qq.com

Abstract

Here, we report a case of cryptococcal meningitis (CM) diagnosed by next-generation sequencing (NGS) of cerebrospinal fluid (CSF) in an immunocompetent patient. The patient developed intermittent fever, headache and worsening inflammatory markers following heart valve surgery, whose condition continued to deteriorate despite empiric broad-spectrum antibiotic therapy was administered. She was finally admitted to the intensive care unit (ICU) with impaired consciousness. *Cryptococcus neoformans* infection was later detected by NGS of CSF. The patient's symptom was improved with anti-cryptococcal therapy, and she finally had a favorable prognosis. This case shows that the patient with fever and headache after cardiac surgery should be alert to intracranial infections after heart valve surgery, and NGS does play an important role in the rapid diagnosis of CM.

Keywords: Cryptococcal meningitis; *Cryptococcus neoformans*; Next-generation sequencing; Heart valve surgery; Immunocompetent

Background

Cryptococcal Meningitis (CM) is a fungal disease that is frequently neglected, according to data, an average of more than 220,000 people are diagnosed with CM each year, and the mortality is as high as 181,100 cases [1]. CM is usually common in immunocompromised patients, such as Human Immunodeficiency Virus (HIV) infected and

organ transplant recipients. But in some cases, immunocompetent individuals are also at risk. Studies have found that HIV-negative patients have a longer duration of symptoms than HIV-positive patients and organ transplant recipients [2]. CM is caused mainly by two pathogens, *Cryptococcus neoformans* and *Cryptococcus gattii* complex, and globally the prevalence of *Cryptococcus neoformans* infections (80%) is significantly higher than that of *Cryptococcus gattii* (<20%). When *Cryptococcus* enters the brain through the blood-brain barrier after proliferating in large numbers, they multiply in the brain and cause meningitis [3]. This case describes an immunocompetent female patient with rheumatic heart disease who developed fever, headache, and consciousness disorders after the heart valve surgery. Despite routine antibiotic treatment, the patient's symptoms still persist. It was not until the Next Generation Sequencing (NGS) was performed in the Cerebrospinal Fluid (CSF) that the patient was identified as CM and underwent targeted treatment before recovering to health. This case demonstrates that the possibility of CM infection should not be ignored in patients with normal immune function after cardiac surgery, and NGS is important in the diagnosis of immunocompetent patients with unexplained fever and headache.

Case Presentation

This case reported a 59-year-old female who was admitted to the hospital with exertional chest tightness, palpitations, and shortness of breath for 4 years, aggravated with bilateral lower extremity edema for 1 month. She had no specific past medical history, no personal or family history of hereditary or infectious diseases, and did not take any medication for a long period of time. The following were the physical examination findings at admission: T 36.2 °C, HR 102 bpm, BP 108/72 mmHg, SPO₂ 95%, atrial fibrillation rhythm, heart sounds of varying intensity, grade 3/6 systolic blowing, diastolic rumbling murmurs and P2 hyperpulsivity were audible at the apical part of the heart. The description of cardiac ultrasonography were as follows: mitral severe stenosis with moderate to severe regurgitation, tricuspid regurgitation with moderate to moderate regurgitation, left atrial enlargement(about 47 mm), and secondary pulmonary hypertension formation(estimated about 51 mmHg). Based on the patient's clinical manifestations, physical examination, and cardiac ultrasound results, she was diagnosed as, rheumatic heart disease and cardiac function of grade III. Due to severe valvulopathy, the patient was undergone mitral mechanical valve replacement, tricuspid annuloplasty, and left atrial decompression on day 16 of admission after a certain degree of recovery in cardiac function.

Postoperative laboratory tests showed a significant increase in major inflammatory markers, but the G test and GM test showed negative results (Table 1). Chest CT suggested bilateral pulmonary exudation and inflammation, whereas the counts of CD3⁺, CD4⁺, and CD8⁺ cells were normal. We empirically provided her anti-infection treatment (piperacillin sodium tazobactam sodium 4.5 g, tid, intravenous drip). On postoperative day 6, the patient began to have intermittent fever, and headache. The cranial nerve and meningeal stimulation sign test were negative. Cranial CT suggested a sixth ventricle formation (Verga ventricle). The patient's inflammatory indicators were further increasing, and blood culture results found the fungal spores (Table 1). Although the primary infection site was not found, anti-fungal treatment (asposfungin 50 mg, qd, intravenous drip) was still administered. However, she was transferred to the Intensive Care Unit (ICU) due to impaired consciousness on the 17th postoperative day.

Table 1: Main inflammatory parameters.

Item	Result on admission	Postoperative cardiology	Results at ICU	Reference range
WBC ($\times 10^9$)	9.95	22.25	12.94	3.5-10
RBC ($\times 10^{12}$)	4.14	3.53	3.03	3.5-5.5
HGB (g/L)	134	113	99	114-163
NEUT ($\times 10^9$)	6.16	18.62	11.39	1.8-6.3
% NEUT	68.8	83.7	88	40-75
MONO ($\times 10^9$)	0.75	1.76	0.63	0.1-0.6
% MONO	8.4	7.9	4.9	3-10
LYMBP ($\times 10^9$)	1.60	1.71	0.85	1.1-3.2
% LYMBP	17.9	7.7	8.6	20-50
PLT ($\times 10^9$)	191	256	202	125-350
CRP (mg/L)	4.75	83.82	21.72	0-5
ESR (mm/h)	21	47	38	0-20
PCT (ng/mL)	0.042	0.11	0.05	0-0.046
IL-6 (pg/mL)	5.7	83.6	3.8	<7
G test (pg/mL)	<37.5			<60
GM test (ug/L)	0.075		0.050	<0.5
Blood culture	No bacterial growth		Fungal spores	

WBC: White blood cells; RBC: Red blood cells; HGB: Hemoglobin; NEUT: Neutrophils; MONO: Monocytes; LYMBP: Lymphocytes; PLT: Platelets; CRP: C-reactive protein; ESR: Erythrocyte sedimentation rate; PCT: Procalcitonin. IL-6: Interleukin-6; G test: (1-3)- β -D-glucan test; GM test: Glactomannan test.

Laboratory tests presented a decrease of inflammatory markers in the ICU (Table 1). The chest and cranial CT results showed similarities with the previous one. However, the patient's condition did not improve, and consciousness disorder was worsening. To further clarify whether there was a possibility of intracranial infection, we conducted a lumbar puncture. The results of Cerebrospinal Fluid (CSF) (Figure 1) indicated that the patient had intracranial infection. Due to the patient's progressive worsening of consciousness to coma, unstable vital signs, and unclear etiology of intracranial infections, we collected CSF specimens and performed metagenomic sequencing of DNA pathogenic microorganisms at Genskey (Tianjin, China) by GenseqPM pathogen high-throughput sequencing platform MGISEQ-200. CSF-NGS identified a fungus, *Cryptococcus neoformans*. The number of sequences was

28932 (**Table 2**). The patient was diagnosed with CM, and administered anti-fungal therapy with fluorouracil (100 mg/kg/d, intravenous drip) and amphotericin B (5 mg/kg/d, intravenous drip). Subsequently, CSF ink staining and culture also confirmed cryptococcal infection (**Table 3**). After 6 weeks of anti-cryptococcal treatment, the patient's symptoms such as headaches improved significantly. Reviewing the routine and biochemical examinations of CSF suggested significant decrease in infection indicators, and the CSF culture had turned negative (**Figure 1**). She was discharged from the hospital, and continued to receive fluconazole (800 mg, qd, intravenous drip) in combination with flucytosine (100 mg/kg/d, intravenous drip) as consolidation therapy in the local hospital. So far, the follow-up has shown that the patient's prognosis was favorable.

Table 2: NGS gene detection of CSF.

Genus	Number of sequences	Relative abundance (%)	Species	Number of sequences
<i>Cryptococcus</i>	32871	99.85	<i>Cryptococcus neoformans</i>	28932

Table 3: CSF ink staining and culture.

Date	2023.3.2	2023.3.13	2023.3.22	2023.4.7	2023.4.19
CSF ink staining	(+)	(+)	(+)	(+)	(+)
CSF culture	<i>Cryptococcus neoformans</i> (+)	<i>Cryptococcus neoformans</i> (+)	<i>Cryptococcus neoformans</i> (+)	(-)	(-)

2023.3.2: Results of the first CSF on postoperative day 18.

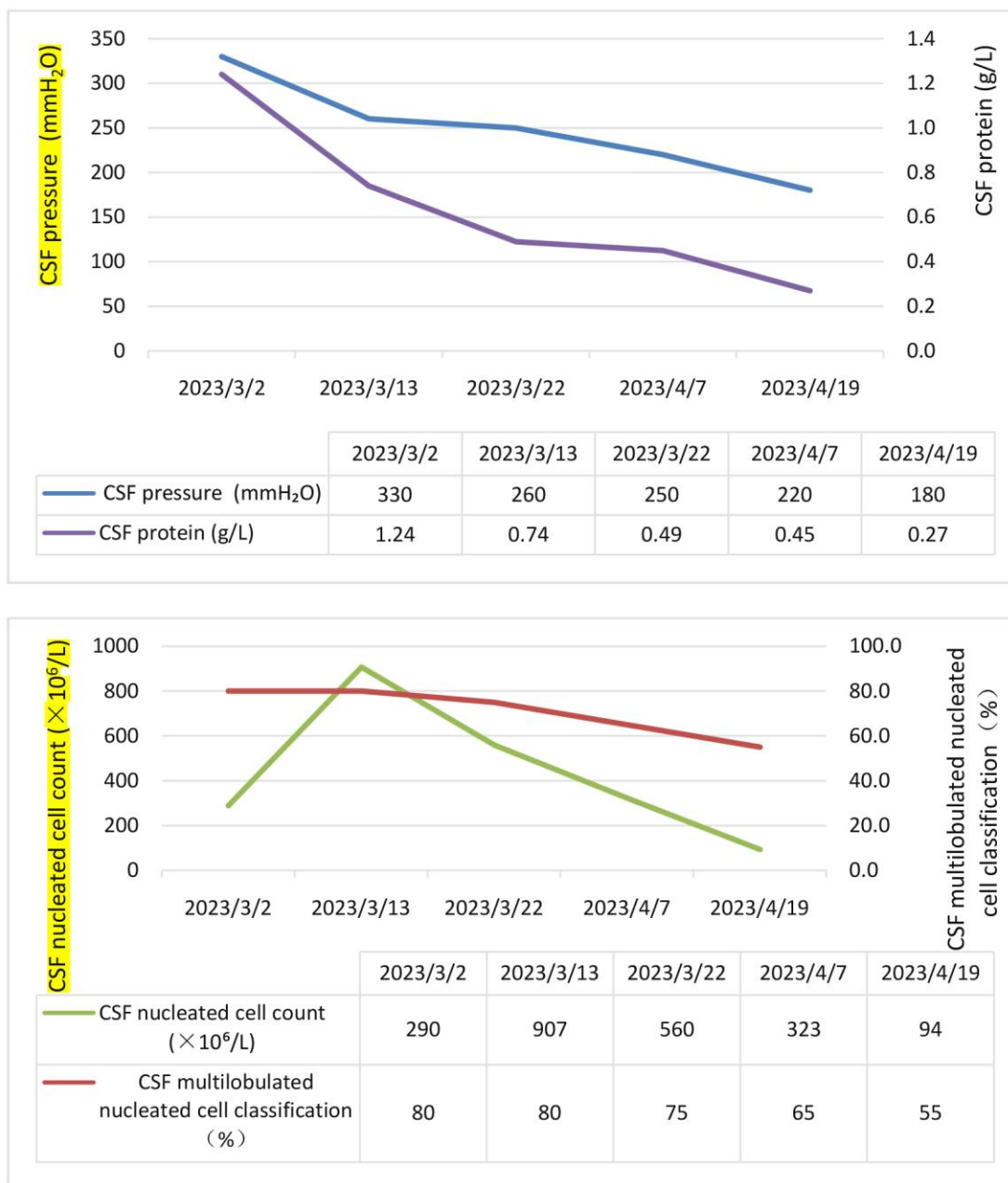


Figure 1: Results of lumbar puncture during treatment.

The first lumbar puncture showed significantly elevated CSF pressure and protein, which returned to normal after 6 weeks of treatment. CSF nucleated cell count as well as multilobulated nucleated cell classification gradually decreased with treatment. 2023.3.2: Results of the first CSF on postoperative day 18.

Discussion

CM is a serious life-threatening opportunistic infection caused by cryptococcal infection [4]. It wasn't until 1951 that Emmons discovered *Cryptococcus neoformans* in soil contaminated with poultry feces, which slowly opened up its

mysteries [5]. After being inhaled from environmental sources, *Cryptococcus neoformans* travel to the alveoli and colonize host cells. Once phagocytes in the host's defenses fail to kill the yeast, the fungus replicate in them and spread into the circulation, ultimately pass through the blood-brain barrier to enter the central nervous system and cause fungal meningitis [6]. The patient in this case underwent heart valve surgery, although the immune function was normal, there was still a risk of infection with *Cryptococcus neoformans*. For the unexplained fever and headache, the conventional test was difficult to diagnose, and NGS, as a new emerging test, might be very helpful for a rapid and accurate diagnosis, which could lead to early treatment of the patient and improved the prognosis.

It is found that patients with non-HIV CM have clinical manifestations of fever, night sweats, weight loss, and sub-acute manifestations in the central nervous system, such as headache and altered mental status. The symptoms persisted for a long time after infection [7]. Among the most common symptoms are headaches, which can last for weeks or even months, and even pseud meningitis in many patients [8]. Elevated intracranial pressure is also often seen, probably due to the blockage of CSF excretory channels after fungal infections. The accumulation of CSF in the perivascular space and subarachnoid space, leading to hydrocephalus [9]. Head CT and MRI lack specificity; CT scans can see diffuse meningeal enhancement, cerebral edema, hydrocephalus, brain parenchyma hypodensity shadow and other signs, but the majority of patients have no abnormality; MRI is more sensitive to the signs [10]. The patient in this case started with recurrent fever and headache. She then developed impaired consciousness with no obvious abnormality in the cranial CT. We did not consider the patient was at risk of developing CM in the beginning due to the nonspecific and polymorphic nature of the clinical presentation. Thus, it posed a challenge for early diagnosis and treatment.

Since the clinical symptoms of CM are nonspecific, an early and timely etiologic diagnosis is difficult. The traditional diagnostic methods for CM can be made directly by microscopy, histopathology, culture, and detection of cryptococcal antigen [11]. In recent years, mNGS, as a novel molecular diagnostic method, has become a standard method for rapid species identification. Due to the high degree of objectivity and timeliness, especially compared to traditional assays, mNGS are not only fast in detection, but also able to differentiate dual infections as well as between *Cryptococcus neoformans* and *Cryptococcus gattii* infections [12]. The specificity of mNGS for diagnosing CM (96%) is slightly lower than that of ink staining and fungal culture (100%), but the sensitivity (93.5%) is much higher than that of them [13]. Despite the fact that fungal culture is currently the "gold standard" for diagnosing CM, the poor sensitivity and time-consuming procedure may delay early diagnosis and treatment. While the result of ink staining is unstable and the positive rate is not high, which is unfavorable to early diagnosis [13,14]. Although the cryptococcal antigens detection is highly sensitive and specific, the results lack objectivity due to their inability to differentiate between *Cryptococcus neoformans* and *Cryptococcus gattii* [14]. Therefore, mNGS plays an important role in the diagnosis of CM. In this case, the patient presented with fever and progressive deterioration of consciousness after heart surgery. In addition to elevated inflammatory indexes, and a positive blood culture result, the remaining test results are all negative. The therapeutic effect was poor after broad-spectrum antibiotics. To identify the cause of impaired consciousness, we promptly conducted CSF-mNGS testing and identified the *Cryptococcus neoformans* infection. The patient's condition improved after anti-*Cryptococcus neoformans* treatment was given, and the prognosis was good.

HIV-infected and non-HIV-infected people with CM have inconsistent clinical manifestations, however, we are still treating non-HIV patients with CM according to the HIV-infected treatments [15]. Early antifungal therapy with intracranial pressure management is very important to the prognosis. Anti-fungal therapy for patients with CM is divided into three parts, including induction, consolidation, and maintenance phases. The currently recommended first-line treatment is flucytosine 100 mg/kg/day for CM for at least 2 weeks in conjunction with amphotericin B 0.7-1.0 mg/kg/day during the induction phase and fluconazole 400-800 mg/day in the consolidation phase for at least 8 weeks. Patients with culture-negative CSF after the induction and consolidation phases of treatment will enter the maintenance phase with fluconazole 200 mg/day for maintenance therapy [16]. Day et al. [15] demonstrated that the combination of amphotericin B with flucytosine in the treatment of CM not only reduced the mortality rate by 40%, but also improved the fungal clearance rate compared with amphotericin B alone. If flucytosine is not available, it can be replaced by fluconazole. The combination remains the most recommended treatment option. The use of amphotericin B has serious side effects, including anemia, renal insufficiency, hypokalemia, and so on. It requires hospitalization and medical management for the duration of the administration, making it vulnerable to the depletion of significant assets and resources after more than 2 weeks of amphotericin B use [17]. In our case, although the patient was not immunocompromised and did not undergo organ transplantation, we followed the currently recommended treatment regimen for HIV-positive CM patients. After 6 weeks of treatment with amphotericin B in combination with flucytosine, she successfully entered the consolidation phase. Then we switched to a combination of fluconazole and flucytosine, due to the consideration of the side effects of long-term amphotericin B use. The results showed that the therapeutic effect of the combination of drugs was significant. The patient's nervous system was restored to normal, and there was no significant damage to liver and kidney functions.

Conclusion

In conclusion, fever, headache, and impaired consciousness may be early manifestations of CM, whereas delayed diagnosis may result from the nonspecific nature of these symptoms. Immunocompetent CM patients after heart valve surgery are rare in clinical practice and easily misdiagnosed. Therefore, early use of NGS for rapid diagnosis of pathogens can help in disease treatment and prognostic regression. This confirms that NGS does play a great role in identifying infectious diseases.

Funding

Supported by the National Natural Science Foundation of China, No. 81860273; the Guizhou Provincial Science and Technology Projects, No. QKHJC-ZK[2022]-260; the Science and Technology Fund of Guizhou Provincial Health Commission, No. gzwkj2021-320; and Guizhou Provincial People's Hospital National Natural Science Foundation, No. [2018]5764-09.

Informed Consent Statement

All investigations on human subjects have been subject to patient consent and patient anonymity was preserved.

Disclosures

The authors declare that they have no conflict of interest. The specimens were used with informed consent from the patient.

References

- 1 [Rajasingham R, Smith RM, Park BJ, Jarvis JN, Govender NP, Chiller TM, et al. Global burden of disease of HIV-associated cryptococcal meningitis: an updated analysis. *Lancet Infect Dis.* 2017;17\(8\):873-81.](#)
- 2 [Bratton EW, El HN, Chastain CA, Lee MS, Poole C, Sturmer T, et al. Comparison and temporal trends of three groups with cryptococcosis: HIV-infected, solid organ transplant, and HIV-negative/non-transplant. *Plos One.* 2012;7:e43582.](#)
- 3 [Kwon-Chung KJ, Fraser JA, Doering TL, Wang Z, Janbon G, Idnurm A, et al. Cryptococcus neoformans and Cryptococcus gattii, the etiologic agents of cryptococcosis. *Csh Perspect Med.* 2014;4:a019760.](#)
- 4 [Park BJ, Wannemuehler KA, Marston BJ, Govender N, Pappas PG, Chiller TM. Estimation of the current global burden of cryptococcal meningitis among persons living with HIV/AIDS. *Aids.* 2009;23:525-30.](#)
- 5 [EMMONS CW. Isolation of Cryptococcus neoformans from soil. *J Bacteriol.* 1951;62:685-90.](#)
- 6 [Liu TB, Perlin DS, Xue C. Molecular mechanisms of cryptococcal meningitis. *Virulence.* 2012;3:173-81.](#)
- 7 [Pappas PG, Perfect JR, Cloud GA, Larsen RA, Pankey GA, Lancaster DJ, et al. Cryptococcosis in human immunodeficiency virus-negative patients in the era of effective azole therapy. *Clin Infect Dis.* 2001;33:690-9.](#)
- 8 [Heyderman RS, Gangaidzo IT, Hakim JG, Mielke J, Taziwa A, Musvaire P, et al. Cryptococcal meningitis in human immunodeficiency virus-infected patients in Harare, Zimbabwe. *Clin Infect Dis.* 1998;26:284-9.](#)
- 9 [Lee SC, Dickson DW, Casadevall A. Pathology of cryptococcal meningoencephalitis: analysis of 27 patients with pathogenetic implications. *Hum Pathol.* 1996;27:839-47.](#)
- 10 [Bicanic T, Harrison TS. Cryptococcal meningitis. *Brit Med Bull.* 2004;72:99-118.](#)
- 11 [Makadzange AT, McHugh G. New approaches to the diagnosis and treatment of cryptococcal meningitis. *Semin Neurol.* 2014;34:47-60.](#)
- 12 [Wilson MR, O'Donovan BD, Gelfand JM, Sample HA, Chow FC, Betjemann JP, et al. Chronic Meningitis Investigated via Metagenomic Next-Generation Sequencing. *JAMA Neurol.* 2018;75:947-55.](#)
- 13 [Gan Z, Liu J, Wang Y, Yang L, Lou Z, Xia H, et al. Performance of Metagenomic Next-Generation Sequencing for the Diagnosis of Cryptococcal Meningitis in HIV-Negative Patients. *Front Cell Infect Mi.* 2022;12:831959.](#)
- 14 [Xing XW, Zhang JT, Ma YB, Zheng N, Yang F, Yu SY. Apparent performance of metagenomic next-generation sequencing in the diagnosis of cryptococcal meningitis: a descriptive study. *J Med Microbiol.* 2019;68:1204-10.](#)
- 15 [Day JN, Chau T, Wolbers M, Mai PP, Dung NT, Mai NH, et al. Combination antifungal therapy for cryptococcal meningitis. *New Engl J Med.* 2013;368:1291-302.](#)
- 16 [Perfect JR, Dismukes WE, Dromer F, Goldman DL, Graybill JR, Hamill RJ, et al. Clinical practice](#)

[guidelines for the management of cryptococcal disease: 2010 update by the infectious diseases society of america. Clin Infect Dis. 2010;50:291-322.](#)

- 17 [Abassi M, Boulware DR, Rhein J. Cryptococcal Meningitis: Diagnosis and Management Update. Curr Trop Med Rep. 2015;2:90-99.](#)

Citation of this Article

Huang JJ, Liu ML, Zhang SS, Yang EY, Wu XY, Gong M, Xianqing Shi XQ and Wu J. Next-Generation Sequencing Technology for the Diagnosis of Cryptococcal Meningitis in a Heart Valve Surgery Female: A Case Report. Mega J Case Rep. 2023;6(11):2001-2008.

Copyright

© 2023 Wu J. This is an open-access article distributed under the terms of the [Creative Commons Attribution License \(CC BY\)](#). The use, distribution or reproduction in other forums is permitted, provided the original author(s) or licensor are credited and that the original publication in this journal is cited, in accordance with accepted academic practice. No use, distribution or reproduction is permitted which does not comply with these terms.