

## Breast Cancer Tumoral Heterogeneity: A Case Report of the Discovery of Multiple Heterogeneous Foci of Invasive Carcinoma Arising Within the Right Breast

Lien C, Gilbert J, Velazquez C\*, and Margheim B

\*Corresponding author: Carolina Velazquez, USA

### Abstract

We report the case of a 50-year-old female with bilateral breast implants who presented with indeterminate, pleomorphic, linear, branching ductal calcifications in the right breast. Following unsuccessful stereotactic biopsy, the patient underwent a right breast excisional biopsy with wireless localization. The biopsy identified ER positive, PR positive, invasive ductal carcinoma (IDC) with mucinous features and ductal carcinoma in situ (DCIS). In order to obtain adequate margins, the decision was made to proceed with bilateral mastectomy with reconstruction and right sentinel lymph node biopsy. Final pathology revealed multiple, heterogeneous foci of invasive carcinoma arising within the right breast including invasive tubular carcinoma (ER and PR positive, HER2

negative), high-grade DCIS and moderately differentiated invasive ductal carcinoma (ER and PR negative, HER2 positive). Ultimately, adjuvant hormonal therapy, HER2 targeted therapy and chemoradiotherapy were recommended.

### Introduction

Breast cancer was the first type of human cancer to have its treatment approach tailored to the molecular profiling of individual tumors. In its early stages, anti-estrogen therapy emerged as a pioneering example of precision medicine; targeting the molecular signature specific to each patient [1]. However, the treatment of breast cancer has been challenging due to the heterogeneity of its molecular and histological features. Two forms of tumor heterogeneity are recognized: inter-tumoral and intra-

tumoral heterogeneity. Traditionally, breast cancer heterogeneity has been primarily understood as a complex disease, with an emphasis on its degree of inter-tumoral heterogeneity [1,2]. This model examines how the disease varies among patients based on differences in the expression levels of Estrogen Receptor (ER), Progesterone Receptor (PR), and Human Epidermal Growth Factor Receptor 2 (HER2) [3-5]. These histological stratifications have enabled the development of tailored treatments that specifically target the expression of these receptors, thereby improving patient outcomes [1,2,6]. Though this classification has been useful in guiding treatment and prognostication, a different approach that focuses on the concept of intra-tumoral heterogeneity has recently emerged. This model addresses the presence of diverse tumor cell populations within a single tumor entity [1,7,8]. Breast tumors, consisting of multiple, coexisting subtypes, are influenced by both the tumor microenvironment and the inherent plasticity of cancer cells [3,4,9]. The clonal evolution model proposes that stochastic mutations in tumor cells lead to adaptation and selection of the fittest clones through natural selection [1,5]. Meanwhile, the Cancer Stem Cell (CSC) model suggests that a subset of cancer cells with indefinite self-renewal ability organizes tumors hierarchically and generates diverse cell types through differentiation pathways [2,10]. These phenotypically distinct subpopulations have led to concerns regarding the success and utilization of different treatment options. Understanding these distinct features regarding inter- and intra-tumoral heterogeneity of breast cancer is critical for future diagnostic and therapeutic strategies that will serve as the foundation for targeted therapy [4,6]. Although it aids in predicting the overall prognosis, there are no

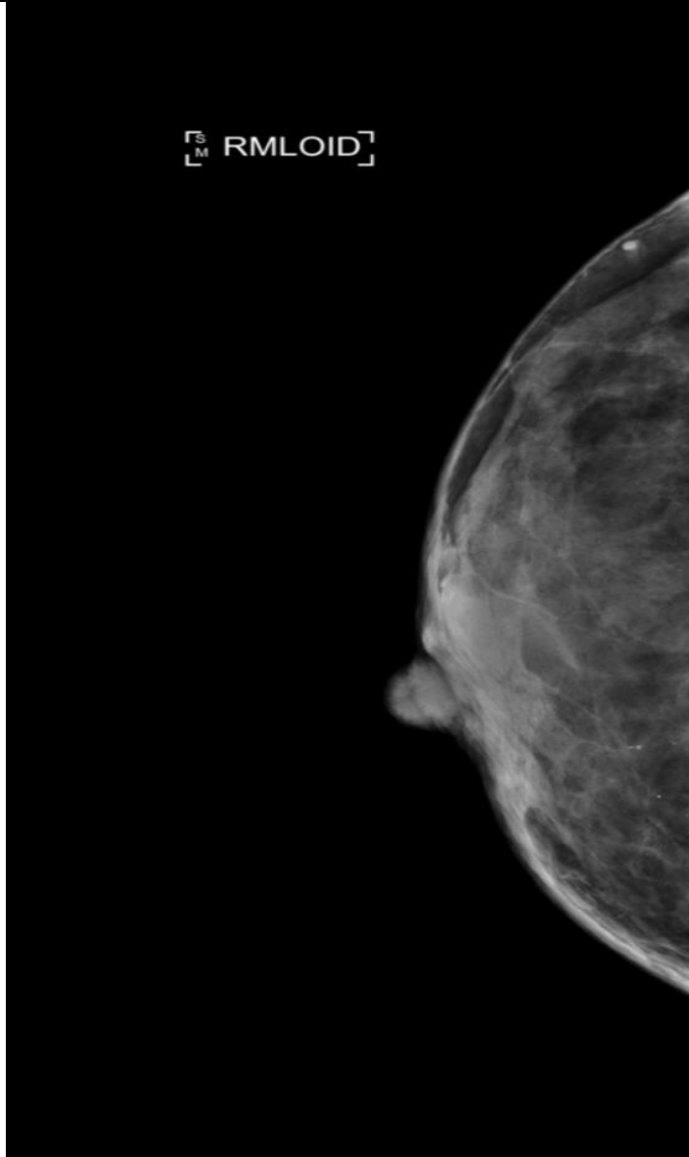
established treatment guidelines for the rare breast cancer subtypes [9]. Thus, treatment guidelines for heterogeneous breast tumors require further research to obtain a broader understanding of the biology of these breast cancer subtypes, ultimately leading to improved outcomes [1,11]. Here, we present a case of a patient with multiple foci of various histologic subtypes with a single breast malignancy.

### Case Presentation

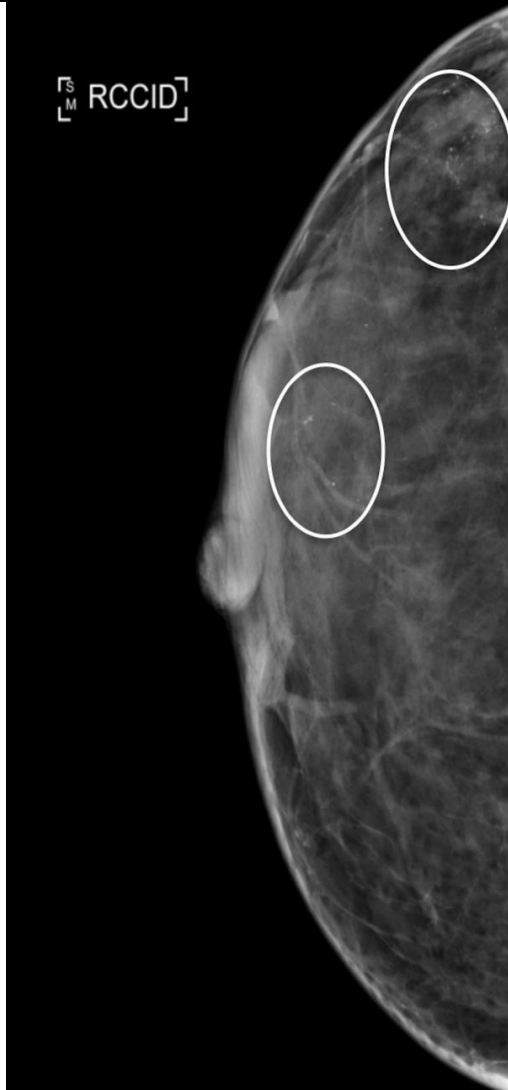
A 50-year-old female with a past medical history of hypothyroidism and bilateral, saline breast implants who presented with grouped right lateral and inferior breast calcifications (Figure 1 and 2) on screening mammography. Upon further imaging, indeterminate, pleomorphic, linear, branching ductal calcifications were noted in the right lateral and inferior breast (Figure 3 and 4). Given these findings, stereotactic biopsy was planned. Despite multiple attempts, a stereotactic breast biopsy of the suspicious areas could not be performed as the criteria for the desired thickness under compression could not be fulfilled (Figure 5). Thus, surgical excision was recommended Figure 1-5. The patient underwent a right breast excisional biopsy with Savi Scout localization. Final pathologic diagnosis revealed right breast calcification at 8 o'clock (Specimen 1) with a 1.3-mm focus of Invasive Ductal Carcinoma (IDC) with predominant mucinous features. Prognostic markers indicated Estrogen Receptor (ER) positivity, Human Epidermal Growth Factor Receptor 2 (HER2) positivity, Progesterone Receptor (PR) negativity, and borderline Ki-67 expression. Ductal carcinoma in situ (DCIS) was present at the deep margin, characterized as intermediate to high grade, cribriform type with central necrosis and micropapillary type with microcalcifications.

Additional margins were obtained (Specimen 2) with the pathology revealing invasive mammary carcinoma with predominantly mucinous features and DCIS, intermediate to high grade. Invasive carcinoma present 3.5 mm from the inked final margin. DCIS was focally present at the blue inked final resection margin. Post-operatively, the patient was sent for genetic testing and was found to be negative for BRCA 1 and BRCA 2. She was counseled on the current standard of care and surgical treatment options, according to the National Comprehensive Cancer Network (NCCN) guidelines. Given the patient's family history of breast cancer, she elected to undergo bilateral mastectomy. The patient ultimately underwent explantation of bilateral breast implants, bilateral mastectomy and right Sentinel Lymph Node Biopsy (SLNB). Final surgical pathology of the left breast mastectomy revealed benign breast tissue without evidence of DCIS or malignancy. Both of the sentinel lymph nodes from the right axilla were negative for metastatic

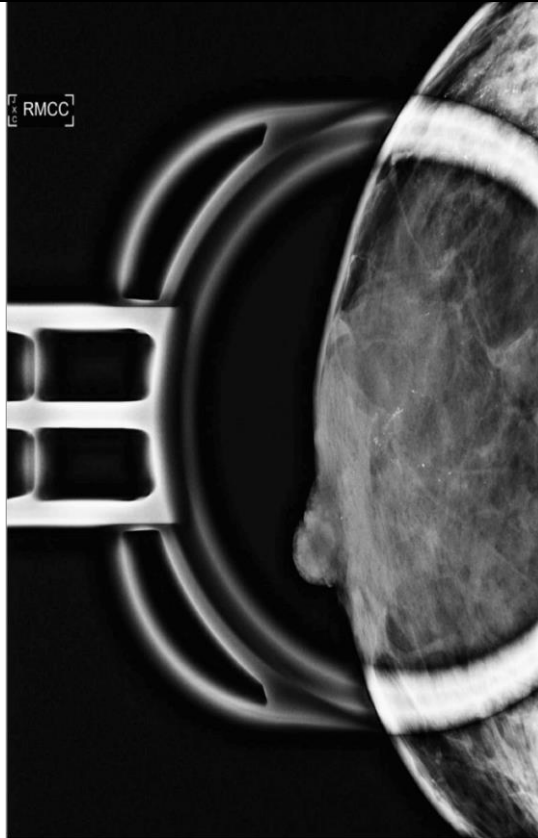
carcinoma. Final pathology of the right breast, at the 8 o'clock position, revealed invasive tubular carcinoma, characterized as well differentiated, ER positive, PR positive and HER2 negative. The deep resection margin was focally positive for DCIS. Separate foci of DCIS were found near the nipple. Additional margins were excised revealing DCIS with intermediate to high grade characteristics with micropapillary, solid and comedonecrosis patterns. The right lateral margin demonstrated a microscopic focus of invasive ductal carcinoma, infiltrating only in angulated glands. Tissue revealed moderately differentiated, ER negative, PR negative and HER2 positive with associated high-grade DCIS. The patient's final pathologic stage was pT1bN0. The diverse morphology and biomarker profile support the diagnosis of two foci of invasive carcinoma. Given this, hormone therapy, HER2 targeted therapy, radiation and chemotherapy was recommended. The patient consented only to radiation and was lost to follow up.



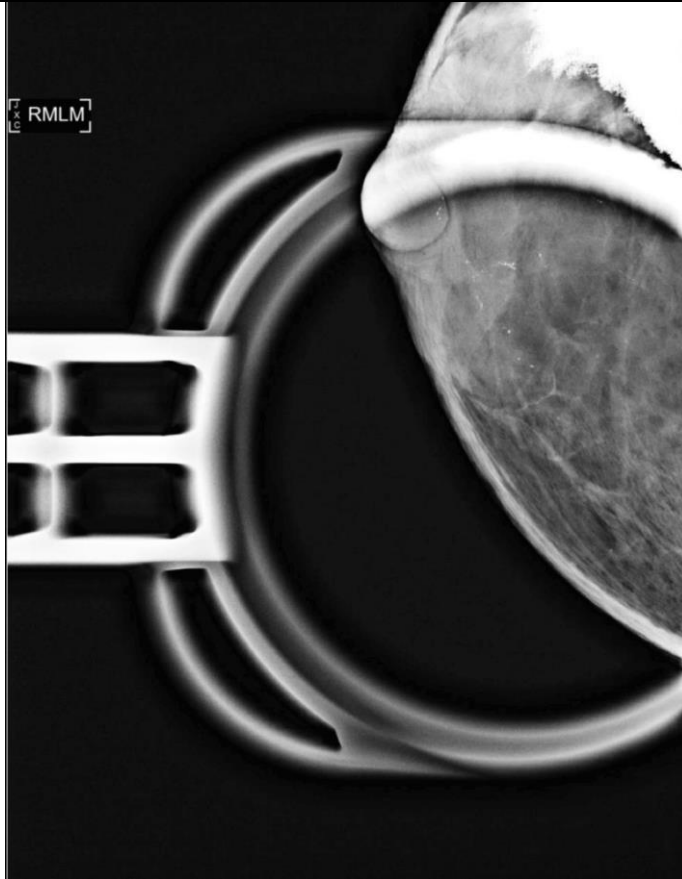
**Figure 1:** Screening Mammogram, Mediolateral Oblique View.



**Figure 2:** Craniocaudal view of screening mammogram with circled areas of concerning calcifications.



**Figure 3:** Diagnostic Mammogram, Craniocaudal View.



**Figure 4:** Diagnostic Mammogram, Mediolateral View.



**Figure 5:** Attempted Stereotactic Biopsy.

### **Discussion**

Tumoral heterogeneity in breast cancer refers to the presence of diverse cell populations within tumors, which leads to variability in molecular characteristics and behaviors [1,12]. This heterogeneity can be categorized into inter-tumoral and intra-tumoral types. Inter-tumoral heterogeneity encompasses a broad spectrum of biological subtypes distinguished by differences in hormone receptor status and HER-2 expression [3,7]. Traditionally, treatment strategies have focused on targeting these specific markers, such as antiestrogen therapy for ER-positive tumors and HER-2 targeted therapy for HER2-positive cancers [7,5]. In contrast, intra-tumoral heterogeneity refers to the coexistence of different tumor cell populations within a single tumor entity, each with

distinct genetic profiles and phenotypes [5]. This complexity, influenced by the tumor microenvironment and cancer cell plasticity, poses significant challenges in treatment [1,3,9]. Despite advancements in molecular characterization that have revolutionized breast cancer treatment, the heterogeneous nature of the disease necessitates refined diagnostic and therapeutic approaches, especially for less common subtypes. Here, we report a 50-year-old female who underwent bilateral mastectomy with right SLNB and evidence of two distinct foci of malignancy on final pathology; one with Invasive Tubular Carcinoma (ITC), ER-positive, PR-positive, and HER2-negative, and another with Invasive Ductal Carcinoma (IDC) that was ER-negative, PR-negative, and HER2-positive,



accompanied by high-grade DCIS. Breast cancer classification by the World Health Organization (WHO) includes up to 21 distinct histological types, each with prognostic implications [13]. The most common type is invasive ductal carcinoma, which constitutes 70-80% of cases. The prognosis of this histologic type varies based on factors like tumor grade and hormone receptor status. In contrast, invasive tubular carcinoma, a rare subtype comprising 1-4% of invasive breast cancers, generally carries a more favorable prognosis due to its smaller size and lower rates of lymph node involvement [10,14]. However, when these two categories of breast cancer appear together in a single entity, concerns for treatment options arise. Through extensive research over the past decades, treatment options regarding intertumoral heterogeneity have been thoroughly recognized. The development of precision therapies that revolve around molecular subtypes such as management based on the primary tumor's ER/PR/HER2 status, and metastatic sites, has led to successful outcomes, prolonging patient survival [8,15]. However, with the ongoing challenges of therapeutic resistance and the discovery of intratumoral heterogeneity in breast cancer, has proven problematic for treatment options and has led to poor prognosis [12,16]. Existing variations within a tumor increase the likelihood that some cancer cells will survive treatment. Additionally, as tumor cells continue to diversify during therapy, they can adapt to the selective pressures imposed by the treatment. This adaptation can result in the development of new resistance mechanisms and eventually lead to a relapse [1,3,7]. Strategies regarding treatment options for intratumoral heterogeneity aim to focus on its ability to combat resistance [12]. Some studies have proposed combination therapy, adaptive therapy,

targeting the tumor's microenvironment, immunotherapy and exposing driver and passenger mutations [9,12,17]. It has also been suggested that to optimize treatment outcomes, intratumor heterogeneity should be evaluated through sequencing technologies at the time of diagnosis for each patient [5,9]. Researchers urge for the need of continuous monitoring of clonal dynamics throughout disease progression and treatment. This approach will help identify genetic alterations that contribute to resistance and enable adjustments to therapy as needed. Though researchers suggest further studies must be done to form a definitive option for the treatment of intratumoral heterogeneity, many have proposed and are moving towards exploiting treatment options that focus on the cancer stem cell model [1,5,17]. Limitations of this case include uncertainty regarding the spatial relationship between the two biopsies obtained from the right breast. It remains unclear whether these biopsies were contiguous sections of the same tumor mass or separate, distinct tumors. Moreover, definitive determination of whether the observed tumor features reflect inter-tumoral heterogeneity (variations between distinct tumors) or intra-tumoral heterogeneity (diversity within a single tumor mass) cannot be conclusively made based on the available histopathological data. Further investigation and possibly additional sampling would be necessary to explain these aspects of tumoral heterogeneity in this specific case. Regardless, the management of rare breast cancer histotypes presents ongoing challenges in clinical practice, given their distinct behaviors and responses to treatment. While conducting prospective studies on rare breast cancers remains impractical due to their rarity, understanding their molecular underpinnings through genomic evaluation could

reveal specific cancer pathways relevant to both rare and more common histologies. This approach holds promise for advancing personalized treatment strategies tailored to individual tumor profiles. Our understanding of tumoral heterogeneity in breast cancer has evolved significantly in recent years, driven by technological advancements and innovative experimental models. However, critical questions remain regarding how heterogeneity influences therapeutic responses and metastasis. Addressing these questions requires larger cohorts and advanced methodologies to explore transcriptional, epigenetic, and proteomic intra-tumor heterogeneity comprehensively.

## Conclusion

Despite advancements in targeted treatments for breast cancer and an improved understanding of tumoral heterogeneity, challenges persist due to the development of resistance and treatment relapse. Further investigation is essential to better clarify the impact of tumor heterogeneity on treatment and ultimately improve outcomes. This case report underscores the need for larger cohort studies and advanced treatment methodologies. Potential strategies include combined therapies and adaptive therapy via continuous monitoring of genetic alterations during treatment.

## References

1. [Turner KM, Yeo SK, Holm TM, Shaughnessy E, Guan JL. Heterogeneity within molecular subtypes of breast cancer. Am J Physiol Cell Physiol. 2021;1:343-354.](#)
2. [Turashvili G, Brogi E. Tumor Heterogeneity in Breast Cancer. Front Med \(Lausanne\). 2017;8:227.](#)
3. [Roulot A, Héquet D, Guinebretière JM, Vincent-Salomon A, Lerebours F, Dubot C, et al. Tumoral heterogeneity of breast cancer. Ann Biol Clin \(Paris\). 2016;1:653-660.](#)
4. [Sahoo S, Ramu S, Nair MG, et al. Increased prevalence of hybrid epithelial/mesenchymal state and enhanced phenotypic heterogeneity in basal breast cancer. iScience. 2024;27:110116.](#)
5. [Yeo SK, Guan JL. Breast Cancer: Multiple Subtypes within a Tumor? Trends Cancer. 2017;3:753-760.](#)
6. [Sarhangi N., Hajjari S, Heydari S, et al. Breast cancer in the era of precision medicine. Mol Biol Rep. 2022;49:10023-10037.](#)
7. [Fumagalli C, Barberis M. Breast Cancer Heterogeneity. Diagnostics \(Basel\). 2021;27:1555.](#)
8. [Hou Y, Nitta H, Li Z. HER2 Intratumoral Heterogeneity in Breast Cancer, an Evolving Concept. Cancers \(Basel\). 2023;9:2664.](#)
9. [Salemme V, Centonze G, Avalle L, et al. The role of tumor microenvironment in drug resistance: emerging technologies to unravel breast cancer heterogeneity. Front Oncol. 2023;17:1170264.](#)
10. [Huang K, Misra S, Bagaria SP, Gabriel EM. Outcomes of patients with invasive mucinous and tubular carcinomas of the breast. Breast J. 2021;27:691-699.](#)
11. [Libson S, Lippman M. A review of clinical aspects of breast cancer. Int Rev Psychiatry. 2014;26\(1\):4-15.](#)
12. [Hassan M, Tutar L, Sari-Ak D, Rasul A, Basheer E, Tutar Y. Non-genetic](#)

- [heterogeneity and immune subtyping in breast cancer: Implications for immunotherapy and targeted therapeutics. Transl Oncol. 2024;47:102055.](#)
13. [Dieci MV, Orvieto E, Dominici M, Conte P, Guarneri V. Rare breast cancer subtypes: histological, molecular, and clinical peculiarities. Oncologist. 2014;19:805-13.](#)
  14. [Work ME, Andrulis IL, John EM, et al. Risk factors for uncommon histologic subtypes of breast cancer using centralized pathology review in the Breast Cancer Family Registry. Breast Cancer Res Treat. 2012;134:1209-20.](#)
  15. [Yersal O, Barutca S. Biological subtypes of breast cancer: Prognostic and therapeutic implications. World J Clin Oncol. 2014;10:412-24.](#)
  16. [Teruya N, Inoue H, Horii R, Akiyama F, Ueno T, Ohno S, Takahashi S. Intratumoral heterogeneity, treatment response, and survival outcome of ER-positive HER2-positive breast cancer. Cancer Med. 2023;12:10526-10535.](#)
  17. [Marusyk A, Janiszewska M, Polyak K. Intratumor Heterogeneity: The Rosetta Stone of Therapy Resistance. Cancer Cell. 2020;13:471-484.](#)

### **Citation of this Article**

Lien C, Gilbert J, Velazquez C, and Margheim B. Breast Cancer Tumoral Heterogeneity: A Case Report of the Discovery of Multiple Heterogeneous Foci of Invasive Carcinoma Arising Within the Right Breast. *Mega J Case Rep.* 2025;8(3):2001-2011.

### **Copyright**

©2025 Velazquez C. This is an Open Access Journal Article Published under [Attribution-Share Alike CC BY-SA](#): Creative Commons Attribution-Share Alike 4.0 International License. With this license, readers can share, distribute, and download, even commercially, as long as the original source is properly cited.