

Adequate Preoperative Radiologic Assessment is Crucial to the Surgical Treatment of Carotid Body Tumor: A Case Report

Mengchao Wei, MD¹, Hui Zhang, MD², Fangda Li, MD², Liqiang Cui, MD², Zhili Liu, MD², Yuehong Zheng, MD² and Rong Zeng, MD^{2*}

¹Department of Surgery, Peking Union Medical College Hospital, China

²Department of Vascular Surgery, Peking Union Medical College Hospital, China

***Corresponding author:** Rong Zeng, Department of Vascular Surgery, Peking Union Medical College Hospital, No.1 Shuaifuyuan, Dongcheng District, Beijing 100730, China, Tel: +86-010-69152501; Fax: +86-010-69152501; E-mail: zengrong@pumch.cn

Abstract

Background: Carotid body tumor (CBT) may manifest in varied forms. Surgical treatment for CBT is challenging, especially for Peking Union Medical College Hospital (PUMCH) type V CBT.

Case summary: In January 2022, a 37-year-old woman was admitted to our hospital with a strip-shaped CBT (3.0×2.4×6.8 cm). The lesion was unevenly enhanced, spanning from the left cranial base to the fourth cervical vertebra, and adhered to the left common carotid artery (CCA), internal carotid artery (ICA) and external carotid artery (ECA) as shown by the computed tomography angiography of head and neck. Before the operation, we planned to open the skull and perform vascular reconstruction and informed the patient the high risks of hemorrhage, nerve injury and intracranial complications. However, during the operation, we found the mass was multicentric with two separated parts and both parts were successfully removed eventually, without vascular reconstruction and opening of the cranial base. None of the above complications occurred.

Conclusion: Adequate preoperative radiologic assessment and individualized management of CBT are essential.

Keywords: Carotid body tumor; Surgical resection; Radiologic assessment

Introduction

Carotid Body Tumor (CBT) is the most common type of paraganglioma in head and neck [1]. It's a vascular tumor type and typically arises at the bifurcation of the internal and external carotid arteries and will encase carotid arteries as it grows [2]. Surgical resection is the standard treatment for CBT but substantial risks including hemorrhage, nerve injury and stroke make it challenging, especially in CBT with a large tumor size and a close adherence to the entire surface of the carotid bifurcation [3,4]. According to the Peking Union

Medical College Hospital (PUMCH) classification, type V CBT, with superior margins above the mastoid tip, has the most amount of intraoperative bleeding, the highest incidence of Internal Carotid Artery (ICA) bypass and overall cranial nerve deficits [5]. Therefore, adequate preoperative assessment is crucial to patients with type V CBT. Here, we report a rare case of successfully resected type V CBT.

Case Presentation

In January 2022, a 37-year-old woman presented with a progressively enlarging mass locating at the left neck over the past nine months. The patient presented no symptoms. She had right thyroid nodules for three years without intervention. The mass locates between the left mandibular angle and the left clavicle. It was strip-shaped with a length of 5 cm and a width of 2 cm. The mass was painless, non-moveable and throbbing. No vascular murmur was heard on the mass upon auscultation. No signs of the neuropathy of hypoglossal and laryngeal nerves were observed. The blood tests were normal. The computed tomography angiography of head and neck reveals a 3.0×2.4×6.8 cm mass with obvious and uneven enhancement, spanning from the left cranial base to the fourth cervical vertebra. The mass seemed to encase the initial segments of left common carotid artery (CCA), left ICA and left External Carotid Artery (ECA)(Figure 1A and B).

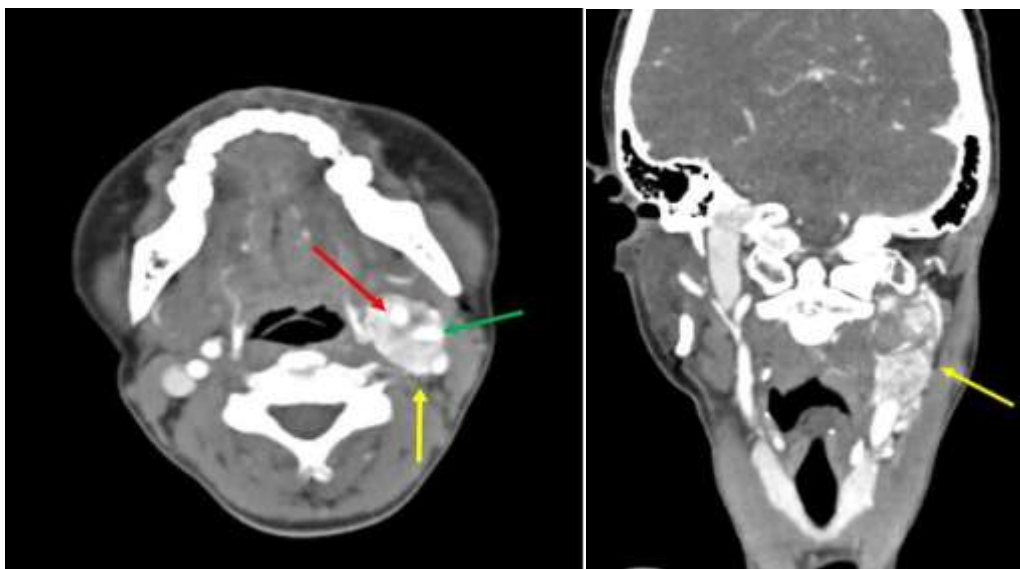


Figure 1: A 37-year old woman, axial (A) and coronal (B) enhanced computed tomography image of the neck demonstrating a carotid body tumor (yellow arrow) with characteristic encasing the internal (green arrow) and external (red arrow) carotid arteries.

The mass in this patient was classified as PUMCH type V, based on that the superior margin of the mass was above the mastoid tip. To achieve complete resection, the abrasion of the temporal bone was considered as a key step to unfold the whole mass and a consultation of otolaryngologist was sent before resection. Besides, intraoperative occlusion of the left CCA and bypass surgery were anticipated to remove the mass and reconstruct blood vessels. A Balloon Test Occlusion (BTO) was performed under local anesthesia before resection to evaluate the patency of anterior and posterior communicating artery. Carotid angiography showed a hypervascular tumor and BTO revealed good compensation of the communicating arteries (Figure 2A and B).

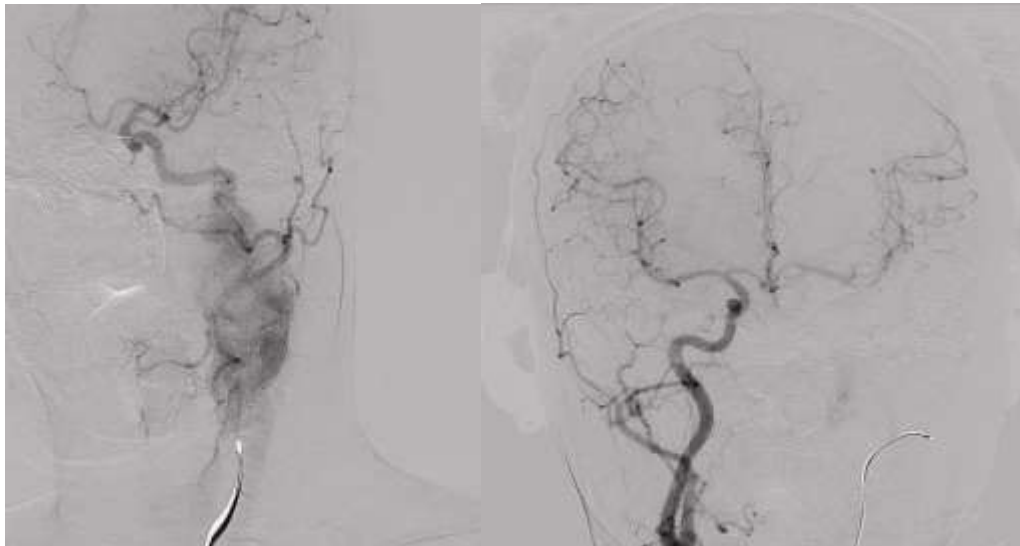
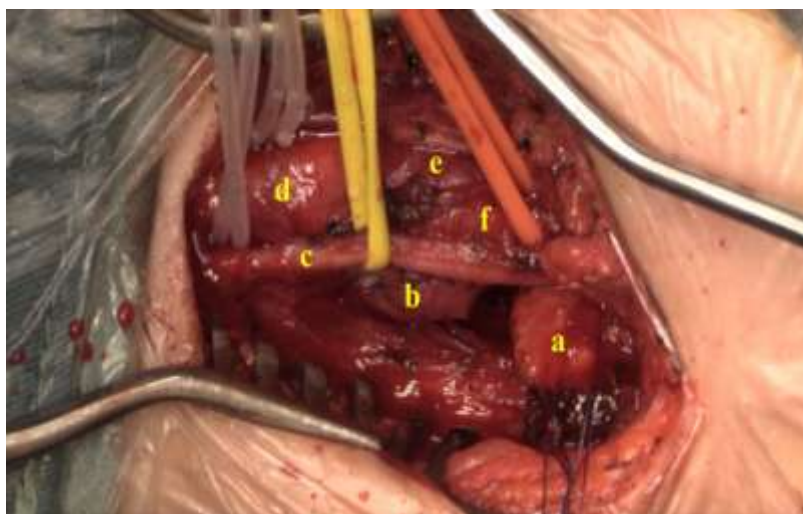


Figure 2: Left carotid artery angiography showed a hypervascular tumor (A) and balloon test occlusion revealed good compensation of the communicating arteries (B).

During the operation, we surprisingly found that the mass was comprised of two parts. The lower part was in a 3 cm diameter, hard and closely adhered to the entire surface of the carotid bifurcation and initial segment of the left ICA. The upper part was 5 cm long, strip-shaped and soft, with its upper end extending beyond mastoid tip. A clear border was seen between the two parts, so we easily separated them (Figure 3A). Since the upper part of the mass was soft, we were able to remove it to the largest extent and inactivated the upper end of the mass with electrocoagulation. Then, we cautiously peeled the lower part of the mass from the artery and vascular reconstruction was eventually not performed (Figure 3B). The vagus and hypoglossal nerves were clearly exposed and protected. Artery clamping was not performed. The blood loss was approximately 100 ml and no transfusion was needed. After the operation, the patient recovered well and no complications of nerve injury and hemorrhage were seen. The patient was discharged on the fourth day after surgery. Based on the postoperative pathology, the final diagnosis of the present case is paraganglioma.



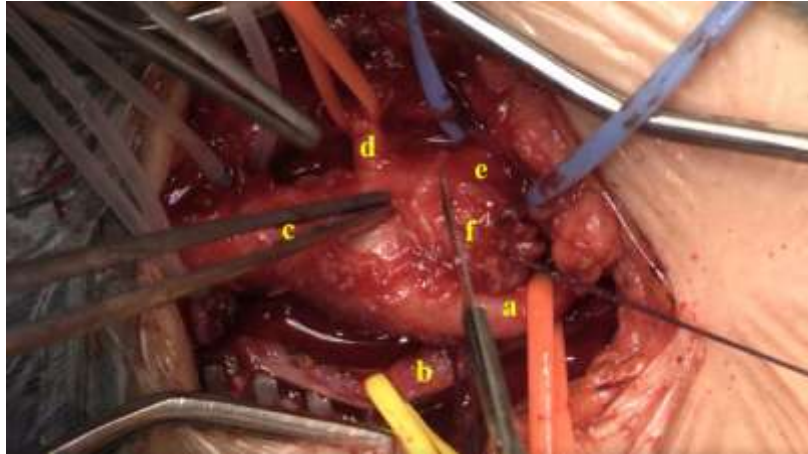


Figure 3: Intraoperative images of the patient. **(A)** A clear border was seen between the two parts of the mass. a. the upper part of the mass; b. the lower part of the mass; c. left vagus nerve; d. left common carotid artery; e. left external carotid artery; f. left internal carotid artery. **(B)** The lower part of the mass was peeled from the artery. a. left internal carotid artery; b. left vagus nerve; c. left common carotid artery; d. left superior thyroid artery; e. left external carotid artery; f. the lower part of the mass.

Written informed consent for publication of clinical details and any accompanying images was obtained from the patient.

Discussion

To the best of our knowledge, the report represents a rare case of successfully resected PUMCH type V CBT. Postoperative pathology indicated that the mass was actually multicentric paraganglioma. The lower one was type III CBT based on PUMCH classification. The upper one was an independent paraganglioma. Eventually, the mass was successfully removed without vascular reconstruction and opening of the cranial base. Surgical risks including hemorrhage, nerve injury and intracranial infection were avoided. Actually, after the operation, we reviewed the computed tomography angiography image of the mass and found that the mass was heterogeneously enhanced. The degree of enhancement of the lower part was much higher than that of the upper part and there seemed to be a borderline between the two parts, indicating the mass was not solitary. Generally, in contrast-enhanced computed tomography, CBT is a homogeneously enhanced mass locating at the carotid bifurcation [6]. However, heterogeneous enhanced CBT cases have been reported in a previous study [7]. In such cases, to acquire detailed information for the CBT operation, dual-source computed tomography was utilized to reveal high-quality imaging of tumor angiogenesis and peripheral vessels of tumor lesions [7]. Therefore, the manifestation of CBT was varied and adequate preoperative radiologic assessment is crucial to the surgical treatment of carotid body tumor.

In fact, this patient suffered from multicentric paraganglioma, which is not uncommon [8]. It can involve the parasympathetic paraganglia of the skull base and neck [9]. In this case, carotid body and a cervical paraganglion were involved. Compared to single paraganglioma, multicentric paraganglioma is associated with a higher rate of postoperative nerve complications and mortality during follow-up [10]. It represents a special issue that should be managed individually. Treatment options including surgery, radiotherapy and observation should all be considered for every individual patient [11].

Conclusion

We reported a rare case of PUMCH type V CBT which was eventually proved to be multicentric and successfully resected. Adequate radiologic evaluation is necessary for individualized management of CBT.

References

1. [Sajid MS, Hamilton G, Baker DM. A multicenter review of carotid body tumour management. Eur J Vasc Endovasc Surg. 2007;34\(2\):127-30.](#)
2. [Wieneke JA, Smith A. Paraganglioma: carotid body tumor. Head Neck Pathol. 2009;3\(4\):303-6.](#)
3. [San Norberto EM, Taylor JH, Carrera S, Vaquero C. Intraoperative embolization with poloxamer 407 during surgical resection of a carotid body tumor. J Vasc Surg. 2012;56\(6\):1782-5.](#)
4. [Shamblin WR, ReMine WH, Sheps SG, Harrison EG, Jr. Carotid body tumor \(chemodectoma\). Clinicopathologic analysis of ninety cases. Am J Surg. 1971;122\(6\):732-9.](#)
5. [Gu G, Wu X, Ji L, Liu Z, Li F, Liu B, et al. Proposed modification to the Shamblin's classification of carotid body tumors: A single-center retrospective experience of 116 tumors. Eur J Surg Oncol. 2021;47\(8\):1953-60.](#)
6. [Berger G, Łukasiewicz A, Grinevych V, Tarasów E. Carotid Body Tumor - radiological imaging and genetic assessment. Pol Przegl Chir. 2020;92\(6\):39-44.](#)
7. [Deng Y, Wang XM, Wu LB, Sun C, Duan YH, Cheng ZP, et al. Significance of the preoperative guidance of dual-source CT in carotid body tumor. Chin Med J \(Engl\). 2010;123\(20\):2816-9.](#)
8. [Boedeker CC, Ridder GJ, Schipper J. Paragangliomas of the head and neck: diagnosis and treatment. Fam Cancer. 2005;4\(1\):55-59.](#)
9. [Jackson CG, Glasscock ME, 3rd, Harris PF. Glomus Tumors. Diagnosis, classification, and management of large lesions. Arch Otolaryngol. 1982;108\(7\):401-10.](#)
10. [Lozano FS, Muñoz A, de Las Heras JA, González-Porras JR. Simple and complex carotid paragangliomas. Three decades of experience and literature review. Head Neck. 2020;42\(12\):3538-50.](#)
11. [Álvarez-Morujó RJ, Ruiz M, Serafini DP, Delgado IL, Friedlander E, Yurrita BS. Management of multicentric paragangliomas: Review of 24 patients with 60 tumors. Head Neck. 2016;38\(2\):267-76.](#)

Citation of this Article

Mengchao W, Hui Z, Fangda L, Liqiang C, Zhili L, Yuehong Z and Rong Z. Adequate Preoperative Radiologic Assessment is Crucial to the Surgical Treatment of Carotid Body Tumor: A Case Report. *Mega J Case Rep.* 2022; 1: 2001-2005.

Copyright

© 2022 Rong Z. This is an open access article distributed under the Creative Commons Attribution License, which permits unrestricted use, distribution, and reproduction in any medium, provided the original work is properly cited.