

**Surviving an Open Metacarpal Fracture in the Middle Ages:
Complicated Hand Injury in an Individual from the Sant Benet de
Bagès Monastery (Barcelona, Spain)**

Wenceslao M CALONGE^{1*} and Joaquim BAXARIAS-TIBAU²

¹Department of Surgery, Hospital Sant Joan de Déu, Barcelona, Spain

²Laboratory of Paleopathology and Paleoanthropology, Archeological Museum, Barcelona, Spain

***Corresponding author:** Wenceslao M. CALONGE, Department of Surgery, Hospital Sant Joan de Déu 2, E-08950 Esplugues de Llobregat, Barcelona, Spain, Tel: 0041 78 901 25 92; E-mail: wcalonge@yahoo.es

Abstract

The osseous remains of an adult male from the medieval cemetery from Sant Benet Monastery (10th -11th centuries CE) show unequivocal signs of an oblique fracture of the third left metacarpal and secondary sclerosing osteomyelitis. A complex high energy mechanism entailed compression and disruption of carpal bones and a probable perilunate luxation. Malunion of the third metacarpal combined shortening and bone bridges between second, third and fourth metacarpals in a peculiar pattern. Abscesses were probably associated and the carpometacarpal, mid carpal and radio carpal joints present signs of focal infection. The natural evolution into ulnar-deviated ankylosis suggests a long-term survival in spite of infection as well as a tolerable, spontaneous outcome in the pre-antibiotic era. Nothing can be gathered about the nature of available treatments, even considering that monasteries were the most important deposit of science in this period.

Keywords: Metacarpal fracture; Open fracture; Hand infection; Paleopathology

Introduction

Rheumatoid conditions and fractures are the most frequent findings in osteopaleopathology. Humeral fractures and Colles fracture of the forearm are the commonest traumatic discoveries on the upper limb [1-4]. There is a bias in the registry: hand and foot fractures are less seen as a consequence of the frailty of their bones; they have been carelessly treated in some excavations. Until the advent of ancient DNA techniques (and the breakthrough of the Denisova cave) [5] they were considered as low value items.

Material and Methods

We present the osseous remains of an adult male from the medieval cemetery from Sant Benet Monastery, Spain (Figure 1A and B). This individual (SFSB – 6594) shows unequivocal signs of an oblique fracture of the third left metacarpal and secondary sclerosing osteomyelitis.

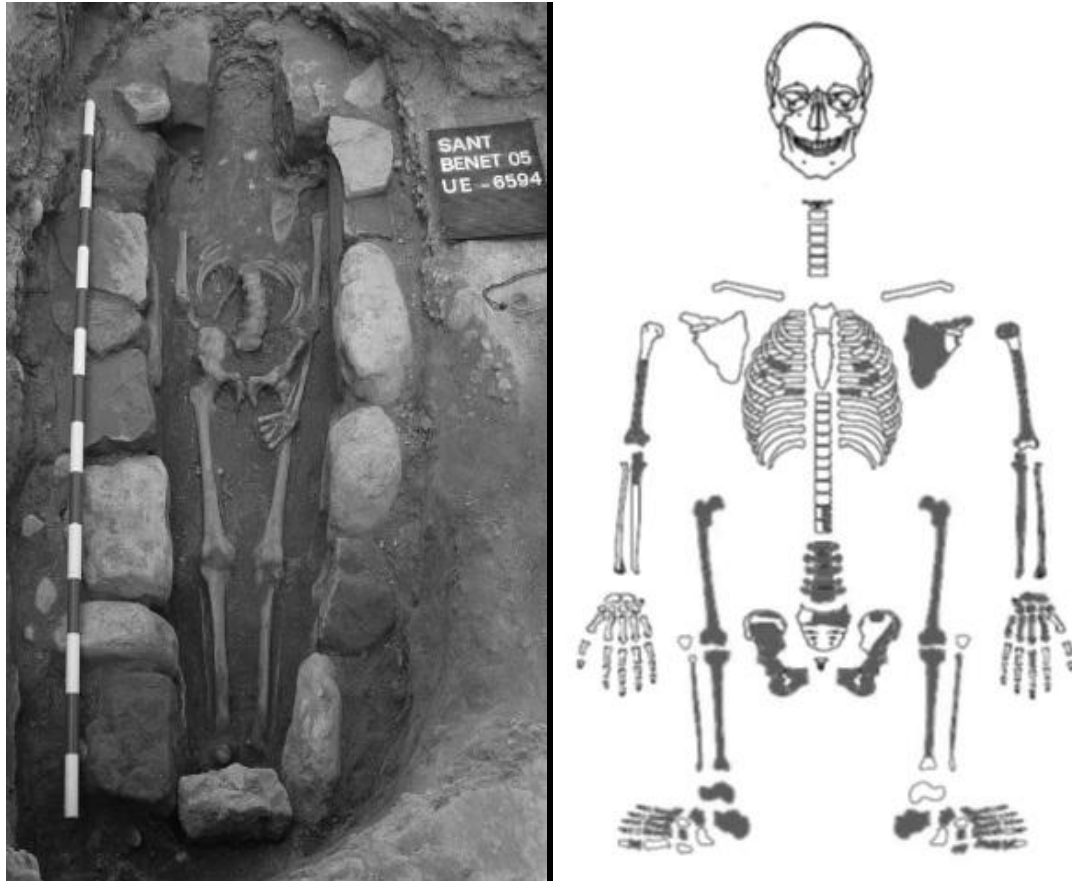


Figure 1A and B: A broad field photography and draft of the osseous findings.

Stratigraphic criteria allow to describe it to 10th -11th centuries CE.

The bones show an acceptable preservation index (IP3=68,2%) but cranium, many vertebrae, clavicles and ribs are absent. Only small fragments from the right humerus and ulna were found. Long bones are robust and show well-marked, femoral muscle insertions. According to Lovejoy (1985) and Ferembach (1979) methods the individual was classified as an adult male.

The third left metacarpal shows a complete oblique fracture (Figure 2A and B). A sloppy inspection of the specimen would have identified five digits in a pentadactily pattern but the thumb is absent. There is no fusion or consolidation apart from the distal portion of the two fragments.

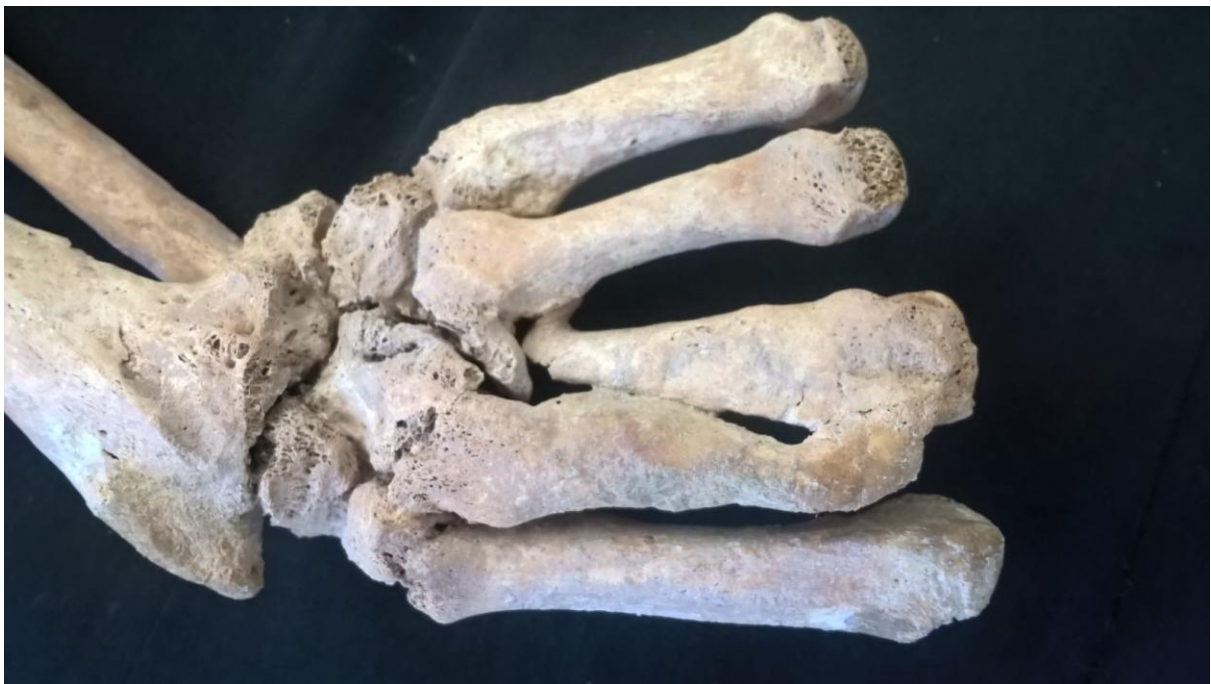
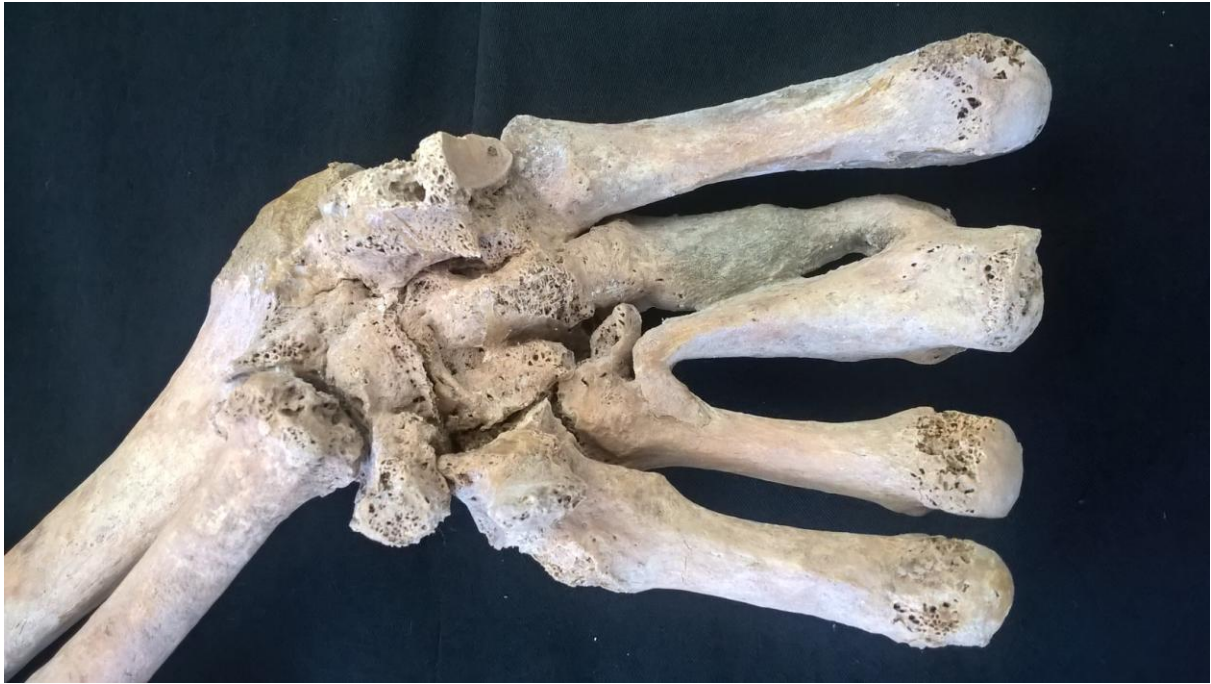
Figure 2A and B: Palmar and dorsal aspect of hand remains.

Results

Some typical signs of osteomyelitis are present. An insufflation as well as fistula orifices communicate to the cavities of intraosseous abscesses in the fractural aspect of the two fragments. It may be inferred that there was a secondary infection that caused pseudarthrosis in the metacarpal diaphysis with bone bridges between second, third and fourth metacarpals in a peculiar pattern ([Figure 3](#)).

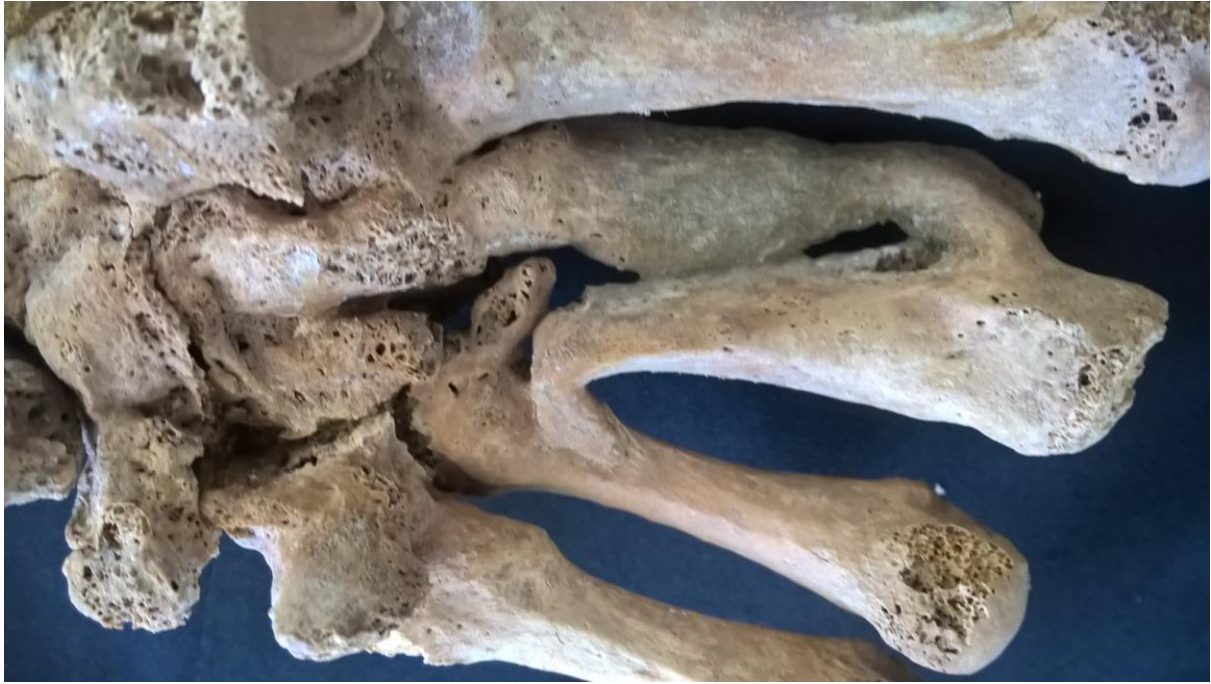

Figure 3: Detail showing the bony bridges at the base of metacarpal bones.

This infection may have been the result of an open fracture with proximal extension and septic arthritis of the wrist. There are signs of periostitis, deformity and fusion of carpal bones and the distal radial epiphysis in a single mass (**Figure 4A and B**). Scaphoid bone is fused in a 30° angle. There are signs of arthrosis of the distal cubital epiphysis. Pronosupination seems to have been very limited.

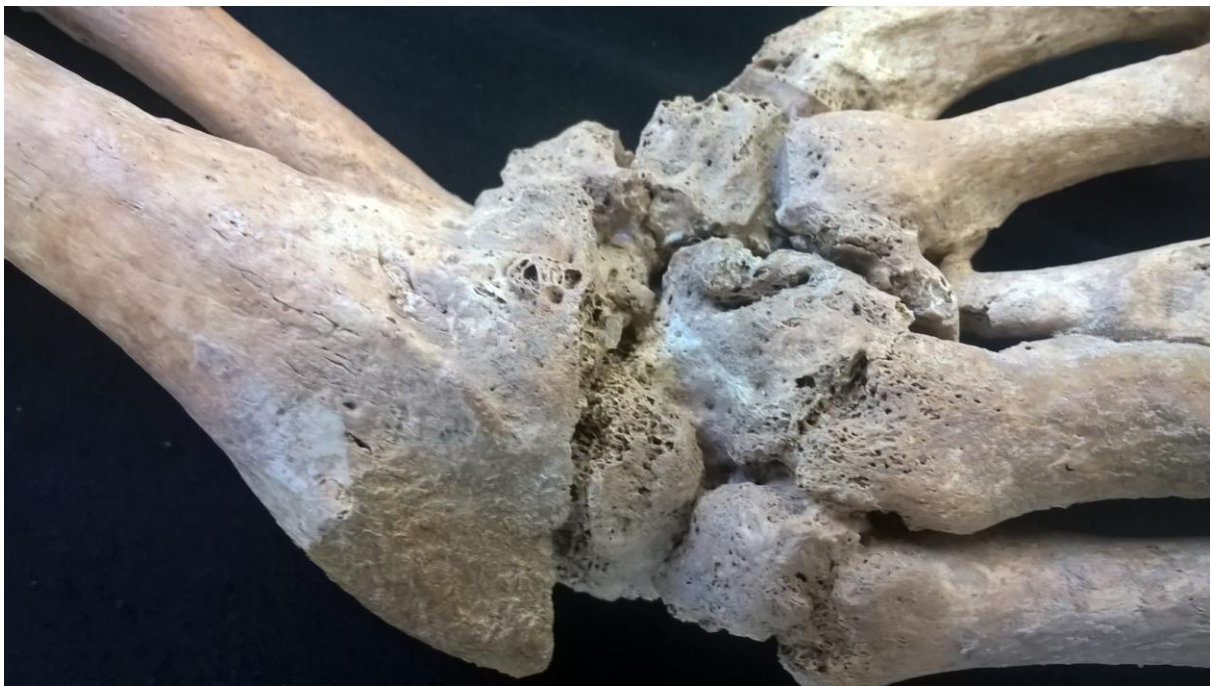

Figure 4A and B: Two details of carpal and wrist involvement.

Radiographic images (**Figure 5**) show cavities of intraosseous abscesses, fistulous orifices, carpal ankylosis and osseous condensation in the distal radio cubital joint.

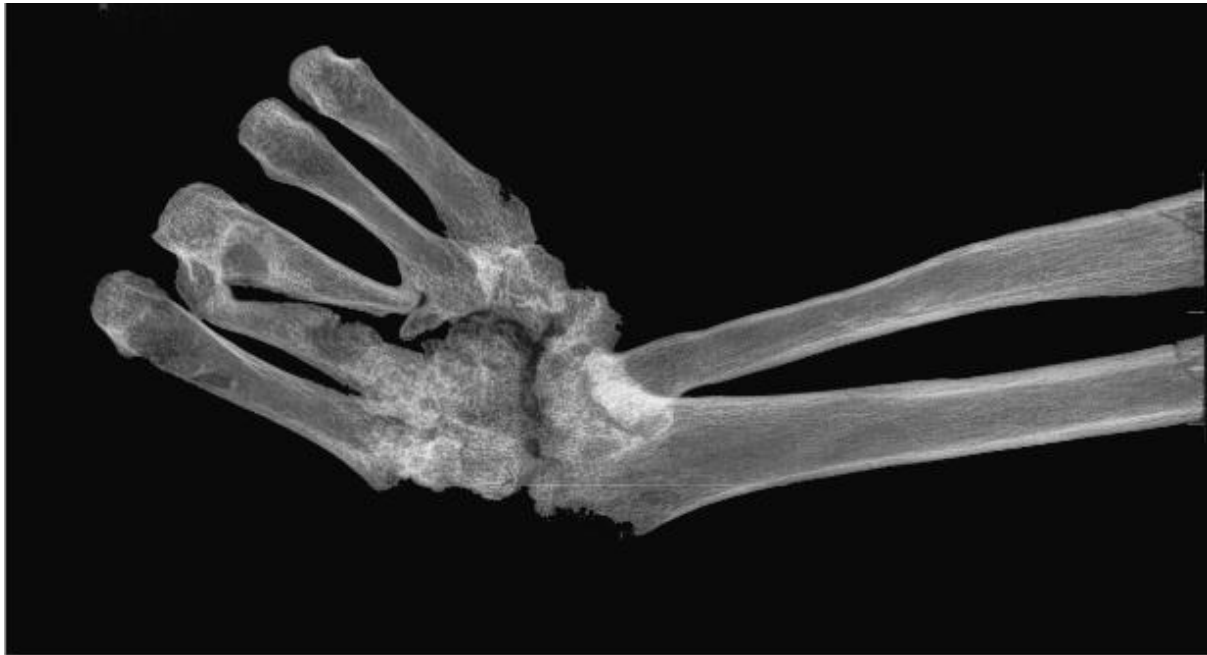

Figure 5: A plain radiography of the specimen.

Discussion

As for the traumatic event it could be hypothesized a complex high-energy mechanism that entailed compression and disruption of carpal bones and a probable perilunate luxation. Due to the direction of the fracture line, an accidental self-injury when holding an object like a log with the palm of the left hand and using an axe with the right (dominant) hand may be excluded. This hand lost much of its function. There were not any movements of flexion/extension and adduction/abduction of the wrist. The natural evolution into ulnar-deviated ankylosis suggests a long-term survival in spite of infection as well as a tolerable, spontaneous outcome in the pre-antibiotic era.

In the light of our current knowledge, little can be gathered about the nature of available treatments in the area, even considering that some monasteries were an important deposit of science in this period. "*De Medicina*", the widely-available, classic treatise by the Roman polygraph Celsus recommended immediate reduction and only 21 days as consolidation period for hand fractures. In case there was some immobilization, it was unsatisfactory in this case. We may suppose that there was some basic cleansing. Treatises like "*Al-Qanun fit-Tibb*" (The Canon of Medicine) of Ibn Sina (Avicenna), "*Practica Chirurgiae*" of Rogerius Salernitanus and "*Cyrurgia*" of Theodoric of Cervia advocate antiseptic cleansing of wounds with wine, vinegar and spices as garlic, organ, rose oil and cinnamon [6-15].

References

1. [Cope JM, Berryman AC, Martin DL, Potts DD. Robusticity and osteoarthritis at the trapeziometacarpal joint in a Bronze Age population from Tell Abraq, United Arab Emirates. Am J Phys Anthropol. 2005;126\(4\):391-400.](#)
2. [Isidro A, Díez-Santacoloma I, Méndez-López J. Approach to the diagnosis of unusual carpal ankylosis from ancient Egypt. Clin Exp Rheumatol. 2015;33\(1\):50-5.](#)

3. [Józsa LG, Farkas GL. Ankylosis of limb joints in a medieval cemetery from Bátmonostor, Hungary. *Anthropol Anz.* 2009;67\(3\):295-303.](#)
4. [Oberlin C, Sakka M. \[The most ancient case of synostosis of the carpal bones: pyramido-lunate synostosis in La Ferrassie man\]. *Ann Chir Main.* 1989;8\(3\):269-72.](#)
5. [Krause J, Fu Q, Good JM, Viola B, Shunkov MV, Derevianko AP, et al. The complete mitochondrial DNA genome of an unknown hominin from southern Siberia. *Nature.* 2010;464\(7290\):894-7.](#)
6. [Carneiro, A, Couto, JA, Mena, C, Queiroz, J, Hogg T. Activity of wine against *Campylobacter jejuni*. *Food Control* 2008;19\(8\):800-5.](#)
7. [Møretrø, T, Daeschel MA. Wine is bactericidal to foodborne pathogens. *J Food Sci.* 2006;69\(9\):M251-M257.](#)
8. [Edwards H. Theodoric of Cervia, a medieval antiseptic surgeon. *Proc R Soc Med.* 1976;69\(8\):553-5.](#)
9. [Keil G. \[Roger Frugardi and the tradition of Langobardic surgery\]. *Sudhoffs Arch.* 2002;86\(1\):1-26.](#)
10. [Buenz EJ, Schnepfle DJ, Bauer BA, Elkin PL, Riddle JM, Motley TJ. Techniques: Bioprospecting historical herbal texts by hunting for new leads in old tomes. *Trends Pharmacol Sci.* 2004;25\(9\):494-8.](#)
11. [Johnston CS, Gaas CA. Vinegar: medicinal uses and antiglycemic effect. *MedGenMed.* 2006;8\(2\):61.](#)
12. [Broughton G 2nd, Janis JE, Attinger CE. A brief history of wound care. *Plast Reconstr Surg.* 2006;117\(7\):6S-11S.](#)
13. [Gordetsky J, Westesson K, Rabinowitz R, O'Brien J. Wine and treatment of genitourinary disease: from antiquity to modern times. *Can J Urol.* 2010;17\(1\):5017-21.](#)
14. [Lang U, Anagnostou S, Helmstädter A. Aromatic vinegars: antiseptics of the past. *Pharm Hist \(Lond\).* 2010;40\(1\):10-2.](#)
15. [Brocke T, Barr J. The History of Wound Healing. *Surg Clin North Am.* 2020;100\(4\):787-806.](#)

Citation of this Article

Wenceslao MC* and Joaquim B. Surviving an Open Metacarpal Fracture in the Middle Ages: Complicated Hand Injury in an Individual from the Sant Benet de Bagès Monastery (Barcelona, Spain). *Mega J Case Rep.* 2022; 1: 2001-2007.

Copyright

© 2022 Wenceslao MC. This is an open access article distributed under the Creative Commons Attribution License, which permits unrestricted use, distribution, and reproduction in any medium, provided the original work is properly cite.